

EVL **GOES GLOBAL**

EVLTM
4 EDITION

13th 14th 15th
FEBRUARY, 2020

"Evolving Techniques, Optimizing Hardware and Maximizing Results"

LEFT ILIAC VENOPLASTY

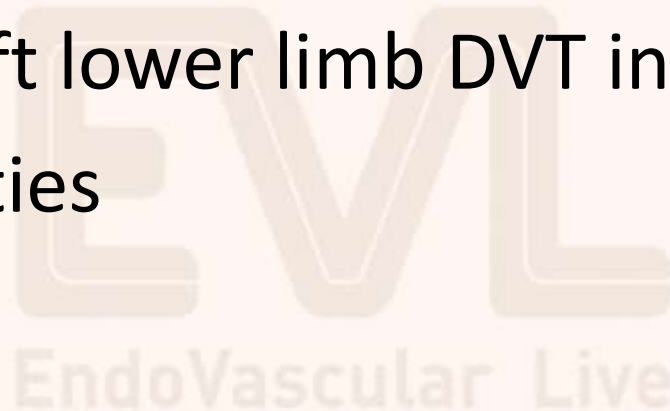
Dr Ajay Yadav

Vice chairman,

Institute of Vascular and Endovascular Sciences,
Sir Ganga Ram Hospital , New Delhi

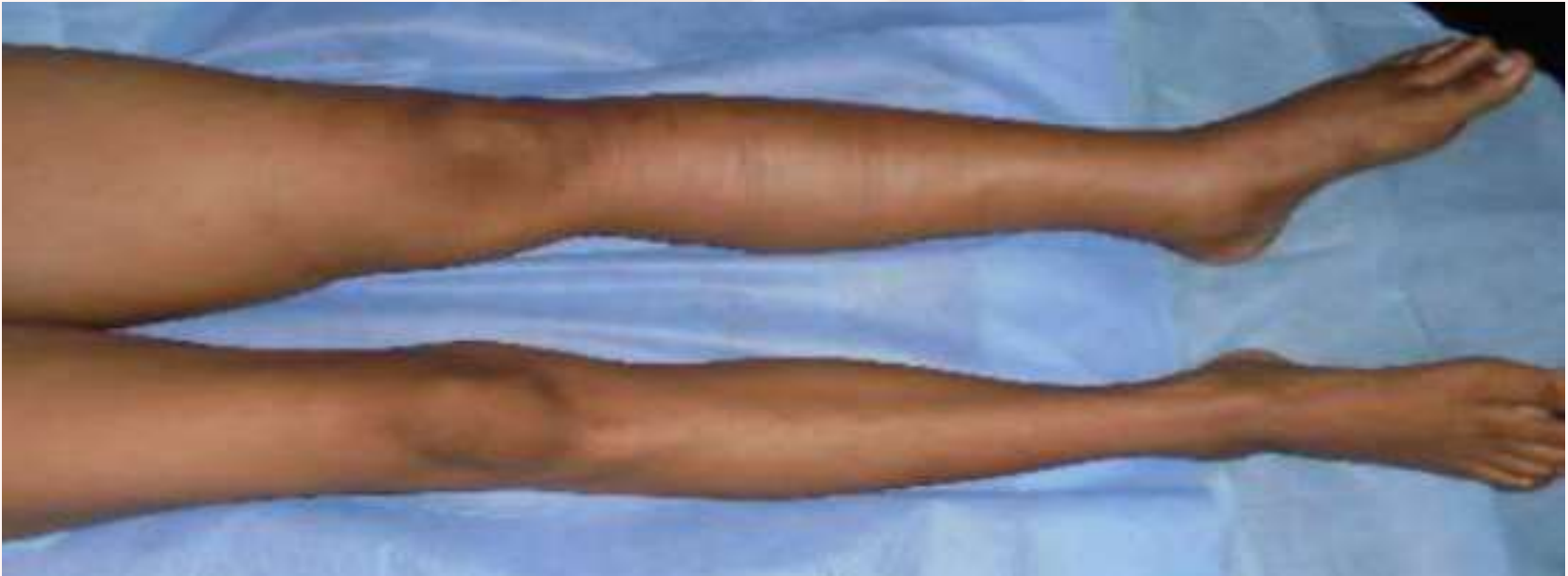Case Description

- 38 years male
- Swelling and pain in the left leg since 1 year
- ? History of left lower limb DVT in past
- No comorbidities



Clinical Examination

- Left thigh and leg swelling



IMAGING

DOPPLER (Left LL):

CT VENOGRAPHY :

Attenuated left CFV, SFV and deep femoral veins

Mild attenuation of popliteal vein and calf veins

Multiple tortuous varicosities along the entire leg

PLAN : Left lower limb venography with left external iliac vein venoplasty/stenting under IVUS guidance through left popliteal vein percutaneous approach under LA



EVLTM 4th EDITION
13th 14th 15th
FEBRUARY, 2020

HARDWARE:

- 6 Fr sheath upgrade to 9 Fr sheath
- Terumo 0.035" / Stiff Terumo
- MPA/ CXI Catheter / IVUS catheter
- Supracore Stiff wire 0.035
- Self Expanding Venous Stent 14mm/16mm
- Non Compliant Balloon 8mm/10mm/12mm/14mm

**THANK
YOU**



"Evolving Techniques, Optimizing Hardware and Maximizing Results"